

# HEPATIC CHANGES IN ABORTIONS AND INFANTS FROM HIV-POSITIVE MOTHERS

## ALTERAÇÕES HEPÁTICAS DE ABORTOS E LACTENTES DE MÃES COM HIV

Paula Ferraz de Oliveira<sup>1</sup>, Gustavo Henrique Nascimento<sup>1</sup>, Luciene de Carvalho Cardoso Weide<sup>1</sup>,  
Analúcia Rampazzo Xavier<sup>1</sup>, Salim Kanaan<sup>1</sup>, Vânia Glória Silami Lopes<sup>1</sup>

### ABSTRACT

**Introduction:** There are a few works in the literature concerning pathological and anatomical alterations of hepatic lesions in necropsies of abortions, stillbirths and children from HIV-positive mothers. **Objective:** To report pathological and anatomical hepatic alterations in fetus and infants from HIV-positive mothers, correlating them with HIV infections, etiologic agents of opportunistic infections and drugs used in different treatments. **Methods:** necropsy material from 15 children and 5 abortions was obtained from the Department of Pathology, Hospital Universitário Antônio Pedro, Fluminense Federal University, from 1986 to 2007. Abortions, stillbirths and children definitions followed World Health Organization criteria. Macro- and microscopic studies were performed after paraffin inclusion with hematoxylin-eosin and other methods (periodic acid-Schiff, reticulin, Gomory's trichrome, silver methenamine, and Sudan stains). All necropsies were completed. **Results:** Results showed macroscopic changes in 13 cases, at least in one category, and microscopic changes compatible with steatosis in 12 cases, necrosis in 7 cases, and colestasis in 4 children and stillbirths. Out of five abortions, two were due to mothers using zidovudina. All patients showed opportunistic infection. **Conclusion:** Macroscopic and microscopic hepatic changes are important in these patients and may not be related to the high frequency of the opportunistic infections. This study will provide subsidies for understanding the pathogenesis of hepatic problems caused by HIV virus, opportunistic agents and drugs used in therapy.

**Keywords:** HIV, opportunistic infections, antiretroviral treatment, hepatic changes, infants.

### RESUMO

**Introdução:** São poucos os trabalhos relacionados à investigação das alterações anatomopatológicas das lesões hepáticas em necropsias de abortos, natimortos e crianças procedentes de mães HIV positivas. **Objetivo:** Descrever as alterações hepáticas em fetos e lactentes procedentes de mães HIV positivas, sob o ponto de vista anatomopatológico, correlacionando-as ao HIV, aos agentes etiológicos causadores de infecções oportunistas e às drogas utilizadas nos diferentes esquemas terapêuticos. **Métodos:** O material utilizado foi proveniente de 15 necropsias de crianças e 5 abortos realizadas pelo Serviço de Anatomia Patológica do Hospital Universitário Antônio Pedro, da Universidade Federal Fluminense, no período de 1986 a 2007. As definições de aborto e lactentes seguem os critérios adotados pela Organização Mundial da Saúde. Foram realizados estudos macroscópicos e microscópicos de fígado, após inclusão em parafina utilizando os corantes hematoxilina e eosina e outros métodos de coloração especial (ácido periódico de Schiff, reticulina, trinômio de Gomory, prata metanamina e Sudan). As necropsias foram completas. **Resultados:** Foram observadas alterações macroscópicas em 13 casos, em pelo menos um critério, alterações microscópicas compatíveis com esteatose foram observadas em 12, necrose em 7 e colestase em 4 das crianças e natimortos. Dos cinco casos de abortos, dois foram procedentes de mães em tratamento com zidovudina. Todos apresentaram agentes de infecções oportunistas. **Conclusão:** As alterações hepáticas macroscópicas e microscópicas são importantes nesses pacientes, e parecem não estar relacionadas à alta frequência de infecções oportunistas. Este estudo fornecerá subsídios para a compreensão da patogenia dos acometimentos hepáticos causados pelo vírus HIV, agentes oportunistas e drogas utilizadas na terapia.

**Palavras-chave:** HIV, infecções oportunistas, tratamento antirretroviral, alterações hepáticas, lactentes.

## INTRODUCTION

The liver is the largest organ in the abdominal cavity and acts both as exocrine gland (releasing secretions) and as endocrine (releasing substances in the blood and lymph system), playing important functions in the sustaining of life, such as participation in the metabolism of carbohydrates (blood glucose control), lipids and proteins, in the processes of synthesis, degradation, detoxification, excretion of substances, conversion of ammonia to urea synthesis and the majority of plasma proteins synthesis<sup>(1)</sup>.

Other liver functions consist in the storage of vitamins (A, B<sub>12</sub>, D, E and K), and minerals (iron and copper) and in the regulation of blood volume, having significant antitoxic action against harmful substances to the organism, such as caffeine and alcohol, and in the processing of drugs<sup>(2,3)</sup>.

The liver tissue, in theory, is not an organ by which the human immunodeficiency virus (HIV) has a predilection, as have for other

organs and cells, however, in the early stage of HIV infection, the hepatocytes are infected and become reservoirs of the virus, allowing its dissemination, with consequent development of acquired immunodeficiency syndrome (AIDS). We know that the presence of HIV in the liver causes minimal effects in healthy individuals, but in immunocompromised, opportunistic infections and cancers, as well as the induction of lesions by anti-retroviral drugs, cause the most diverse symptoms and signs of aggression<sup>(4,5)</sup>.

There are few reports of liver abnormalities in HIV positive children in the literature. Few studies have shown that the liver of patients exhibits a broad spectrum of histologic similarity to those found in adults changes. Morphological abnormalities of injuries vary by specific opportunistic infections to malignancies. Other lesions, although not specific, are probably related to immunosuppression or HIV positive host or iatrogenic causes<sup>(6)</sup>.

Few works have a non-specificity of histological findings including focal necrosis, portal lymphocytic infiltration, hyperplasia of Kupffer cells and hepatic steatosis<sup>(7,8)</sup>. The significance of steatosis does not seem to be related to the use of antiretroviral drugs used in the therapeutic regimen, but rather to malnutrition and infection.

<sup>1</sup>Department of Pathology, Medical School of the Universidade Federal Fluminense (UFF/HUAP) – Niterói (RJ), Brasil.

Some authors suggest that of the histological alterations, the macrovesicular steatosis is the most common microscopic finding in the liver of HIV positive children<sup>(6,7)</sup>.

Other inducer of hepatic injury is the presence of infections by opportunistic agents, being the most common in HIV positive patients: presence of tubercle bacilli (*Mycobacterium tuberculosis*, *Mycobacterium avium intracellulare*), fungi (*Cryptococcus neoformans*, *Histoplasma capsulatum*) and viruses (*Cytomegalovirus*, mainly). Viriyavejakul P et al.<sup>(7)</sup>, through the study of 117 necropsies of adult HIV-positive patients, observed opportunistic infections in 47% of cases, cryptococcosis, tuberculosis and cytomegalovirus in 21.4; 16.2 and 5.1%, respectively. The authors call attention to the absence of hepatic pathological changes in the infection by *Cryptococcus neoformans*.

Viriyavejakul et al.<sup>(9)</sup> found the presence of severe hepatotoxicity, liver failure or exacerbation of the different hepatitis viruses in co-infected HIV positive in 755 patients. In this work was observed a direct correlation between increased alanine aminotransferase and increased T CD4<sup>+</sup> cells counted in patients with severe hepatotoxicity, as well as a higher incidence of severe liver injury after antiretroviral treatment.

In hepatic histological alterations induced by the use of zidovudine in HIV positive patients, we observe the occurrence of intracellular edema, degeneration of vacuolar and fat microvacuolar with homogeneous distribution by the hepatic lobules. These lesions were progressively larger as the treatment time extension<sup>(10)</sup>.

Now the effects of antiretroviral Indinavir were evaluated in a study on pregnant test subjects, which showed that, according to the dose of the drug, the hepatocytes showed heterochromatin cores, and some fatty infiltration, congestion of the sinusoids and portal swelling<sup>(11)</sup>.

All the inhibitors of reverse transcriptase nucleoside analogues (abacavir, didanosine, lamivudine, stavudine and zidovudine) cross the human placenta, reaching levels similar to those observed in umbilical cord and maternal blood at first reach the liver parenchyma<sup>(12)</sup>. From the observations of the aforementioned study and others<sup>(13-15)</sup>, the review of autopsies of abortions from HIV positive mothers became important research with respect to antiretroviral therapy in these patients and its implications in the analysis of factors related to vertical transmission, and emphasize the effectiveness of certain interventions to decrease of the incidence of vertical transmission, such as maternal antiretroviral therapy in breastfeeding populations and early cessation of breastfeeding<sup>(15-17)</sup>.

Viral diseases transmitted by sexual contact are a serious public health problem worldwide. We must remember that pregnancy does not confer immunity against these diseases, instead, they are most prevalent during pregnancy. The immune system during pregnancy is altered, so infections are a major risk to both mother and fetus. It is essential we take into consideration the potential for vertical transmission from infected mothers, for transmission to the fetus or newborn occurs during the prenatal period (through the placenta), intranatal (contact with blood and secretions) and postnatal (via lactation)<sup>(16,17)</sup>.

As important as the maternal risk is the potential impact that these diseases have on the development of pregnancy, not

infrequently resulting on miscarriage, fetal death in utero and premature birth, among other complications for both mother and fetus.

Some authors have reported the importance of amniocentesis and breastfeeding on vertical transmission, and suggest that race and Rh blood factor type may be genetic markers of the susceptibility to infection<sup>(18)</sup>.

In a study in which 51 placentas from HIV positive mothers treated with zidovudine, nevirapine and untreated were evaluated and compared, there were no significant gross lesions and no significant decreases were found in the dimensions of the placental disc. The most commonly found inflammatory lesion was chorionamnionite and noninflammatory was cytotrophoblastic hyperplasia<sup>(19)</sup>. Currently, it is assumed that deaths from HIV have decreased as well as deaths from opportunistic infections. On the other hand, there was an increase in the number of deaths unrelated to HIV disease such as liver, heart and kidney diseases<sup>(20)</sup>.

Just as there are few studies addressing the pathological changes in HIV positive children, little is known about miscarriages or studies with stillbirths of HIV positive mothers. Given the difficulty in finding reports in the literature on the subject, this work had as its general objective to describe, from the anatomopathological point of view, the hepatic alterations in necropsies of abortions and stillbirths coming of HIV-positive mothers and children with AIDS.

## OBJECTIVE

We have aimed to: register hepatic lesions from the point of view of macro and microscopic; correlate the hepatic changes to infection by HIV or their respective opportunistic agents; examine the relation between the drugs used in different therapeutic regimens with hepatic changes; and correlate hepatic abnormalities found in autopsies of HIV positive children with abortions from HIV positive mothers.

## METHODS

A retrospective study was performed in 15 autopsies of livers coming from HIV positive children and 5 autopsies of abortions from HIV positive mothers were performed at the Department of Pathology, at the Hospital Universitario Antonio Pedro (HUAP), at the Universidade Federal Fluminense, in the period of 1986 to 2007.

The material selection was made from clinical and laboratory data obtained from medical records in the hospital archives. The macroscopic study of the liver was obtained from autopsy findings, including photographic documentation. The microscopic analysis was performed after selection of slides stained with hematoxylin-eosin and other special staining techniques filed in the Department of Pathology, HUAP.

## Clinical and laboratory diagnosis

The definition of AIDS cases is based on clinical and laboratory data. Clinically, it is based on the diagnostic criteria according to the standards of the Centers for Disease Control (CDC)<sup>(21)</sup> for the evaluation of HIV infection in children (**Tables 1 and 2**).

The child is considered HIV infected if:

1. Has less than 18 months old, is seropositive for HIV or child of a HIV-positive mother, with positive results in two samples (excluding cord blood) of at least one of the following tests: culture for HIV, Polymerase chain reaction (PCR) to HIV<sup>(22)</sup>, p24 antigen; or
2. Meets the diagnostic criteria for AIDS by the case definition of the CDC 1987<sup>(23)</sup>, namely:
  - Age greater than or equal to 18 months old and HIV positive mother or acquired HIV through blood products or have other form of transmission known (eg., Sexual contact). Also, are seropositive for HIV, with confirmation by repeated enzyme immunoassays and confirmatory test (*Western blot* or immunofluorescence); or
  - Meets any of the criteria described in Section 1.

Asymptomatic children and who do not obey the diagnostic criteria for HIV infection were classified as:

- a) With perinatal exposure (E): younger than 18 months old HIV-seropositive, asymptomatic, do not meet the above criteria for HIV infection;
- b) Seroconverter (SR): if the child born to HIV-infected mother is HIV positive, that is, two or more negative enzyme immunoassays (ELISA test) between 18 months or a negative test after 18 months, with no other laboratory evidence of infection symptoms of HIV or AIDS.

### Necropsies

The autopsies were complete. After the macroscopic study, the material was fixed in a formol solution at 10%, and subsequently the fragments received the usual histological processing until the paraffin embedding.

The prepared paraffin blocks were cut with a five microns thickness and the slides were prepared for routine staining with hematoxylin-eosin.

Other special methods of staining were used for microscopic analysis of liver changes: periodic acid-Schiff (PAS), reticulin, Gomori trichrome, methenamine silver and Sudan.

### RESULTS

The main macroscopic and microscopic changes observed in liver tissue obtained from pediatric autopsies performed in HIV positive patients are summarized in **Tables 3 and 4**, respectively.

The opportunistic infection associated with HIV more prevalent among the cases studied was the Cytomegalovirus (CMV disease), been observed in all 15 postmortem cases evaluated. Then, histoplasmosis was found in 2 of 15 cases and finally tuberculosis in only one case (**Table 5**).

Five autopsies of abortions from HIV positive mothers, in which was reported the clinical and histopathologic analysis of each case (**Table 6**) were performed. Of the five cases evaluated, three were from HIV positive mothers. In one case (Case 2) with ongoing clinical diagnosis of AIDS, cytomegalovirus, accompanied by severe steatosis was observed. In another case (Case 4), the mother was HIV positive in retroviral treatment for two months, and hospitalized for toxemia. The histopathological analysis of this case showed the presence of cholestasis. In the last case (Case 5) of HIV positive mother investigated, a evidence of steatosis, cholestasis and hepatitis was observed.

The **Figure 1** portrays the main hepatic microscopic changes found in 1 of 15 cases studied of autopsy from HIV-positive infants. Loss of lobular structure (**Figure 1A**) in presence of vacuoles (**Figures 1B and 1G**) was observed deflecting the core to the periphery of the cell and increased cell volume (**Figure 1B**); Cholestasis was

**Table 1** – Classification of pediatric AIDS, modified of Centers for Disease Control and Prevention<sup>(21)</sup>

Immunodepression	Clinical categories			
	N = no symptoms	A = mild symptoms*	B = moderate symptoms#	C = severe symptoms <sup>§</sup>
1. Absent	N1	A1	B1	C1
2. Moderate	N2	A2	B2	C2
3. Severe	N3	A3	B3	C3

\*Category A: lymphadenopathy, hepatosplenomegaly, dermatitis, parotid gland enlargement, recurrent upper respiratory infection; #Category B: anemia, neutropenia or thrombocytopenia for more than 30 days, meningitis, pneumonia or sepsis (single episode), oral candidiasis for more than two months in children older than six months, cardiomyopathy, chronic or recurrent diarrhea, hepatitis, stomatitis herpetic (more than one dermatome), nephropathy, norcardiose, fever for more than a month, disseminated varicella, toxoplasmosis, HSV or CMV under one month of age; <sup>§</sup>Category C: Children with any of AIDS defining illnesses.

**Table 2** – Immunodepression associated with levels of CD4, Centers for Disease Control and Prevention<sup>(22)</sup>

Immunodepression	< 12 months old		1–5 years old		6–12 years old	
	CD4		CD4		CD4	
	Total	%	Total	%	Total	%
1. Absent	> 1500	> 25	> 1000	> 25	> 500	> 25
2. Moderate	750–1499	15–24	500–999	15–24	200–499	15–24
3. Severe	< 750	< 15	< 500	< 15	< 200	< 15

**Table 3** – Macroscopic alterations found in the anatomopathological study of the liver of pediatric autopsies in HIV positive patients (n = 15)

Parameters	Macroscopic alterations
Weight	Variation of 76 to 1300 g in the 15 cases
Limits	Exceeding 2 to 9 cm the Border Costal Law in 12 cases, being found a mean of 9 cm
Color	Brownish staining in 14; wine stain in 3; yellowish areas in 12
Capsule	Smooth, bright and transparent in 15 cases
Cut surface	Same coloration of the outer surface in 15, 14 cases of smooth surface and 1 with tiny granulations. Focal area of necrosis with diffuse distribution in 1 case
Consistency	Normal in 7 cases; increased in 2; decreased in 3

**Table 4** – Microscopic changes found in the pathologic examination of the liver in pediatric autopsies in HIV positive patients (n = 15)

Parameters	Microscopic alterations
Lobular structure	- Preserved in 8 cases - Altered in 3, one with fibrosis determining nodes and one with multifocal areas of necrosis
Gross cytoplasmic vacuolization	- Present in 13 cases
Hepatocyte necrosis	- Present in 7 cases
Intracellular cholestasis	- Present in 4 cases
Inflammatory infiltrate: location	- Periductal in 1 case - Intralobular in 13 cases - Reaching the liver parenchyma in 1 case - Portal in 6 cases
Inflammatory infiltrate: predominance	- Mononuclear with lymphocyte predominance in 7 cases - Neutrophilic in 5 cases
Kupffer cells	- In 6 cases hyperplastic - Standard 5 cases
Portal space	- Displays necrosis in 1 case - Absence of influx in 1 case - Influx predominantly neutrophilic inflammation in 4 cases
Capsule	- Areas with inflammatory influx in 5 cases - Necrosis in 3 cases

**Table 5** – Opportunistic infections associated with HIV in pediatric necropsies

Opportunistic infections	
Histoplasmosis	2 of 15 cases
Cytomegalic cell disease	15 of 15 cases
Tuberculosis	1 of 15 cases

**Table 6** – Necropsies of coming abortions of HIV-positive mothers (n = 5)

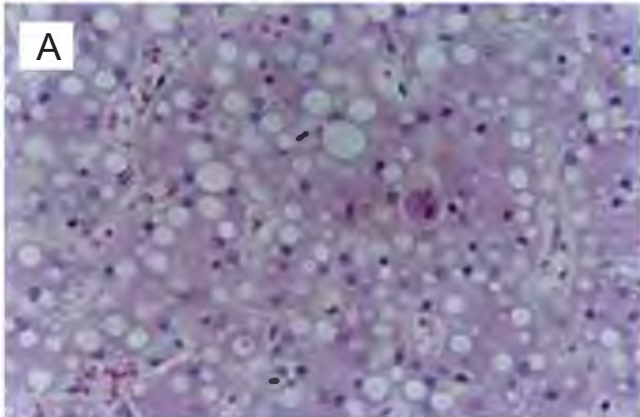
Case	Histopathological analysis
Case 1 (F93.32)	Hepatocytes preserved. Lobular structure preserved. Nuclear vacuolization. Sinusoidal congestion and lobular vein center.
Case 2 (F96.011)	Liver showing intense steatosis, lobular loss of structure. Microvacuolization with core shifted to the periphery. In areas, presence of increased cell size and with clear halo and basophilic intranuclear inclusion. AF occupying the space around the portal vein, being mononuclear. Kupffer cells hypertrophied, congested sinusoids and Disse space invaded by AF. Capsule thickened with mild AF.
Caso 3 (F96.140)	Advanced degree of autolysis. Loss of lobular structure. Cholestasis. Hepatocytes autolysed by the advanced degree of fetal maceration. Kupffer cell hypertrophy. Loss of lobular structure. Cholestasis. Hepatocytes autolysed by the advanced degree of fetal maceration. Kupffer cell hypertrophy. Portal space with mononuclear inflammatory influx and marked degree of fibrosis with mononuclear cell influx and marked degree of fibrosis.
Caso 4 (F04.32)	Capsule thickened with increased cellularity with some lymphocytes. The liver parenchyma shows hepatocytes with large cytoplasmic vacuoles deflecting the core to the periphery of the cell. Call further attention, multiple focal areas of lymphocytic inflammatory influx. Sometimes we observed the presence in the cytoplasm of hepatocytes of fine-grained greenish-brown (cholestasis). Massive steatosis, cholestasis and hepatitis.
Caso 5 (F07.04)	

AF: inflammatory influx.

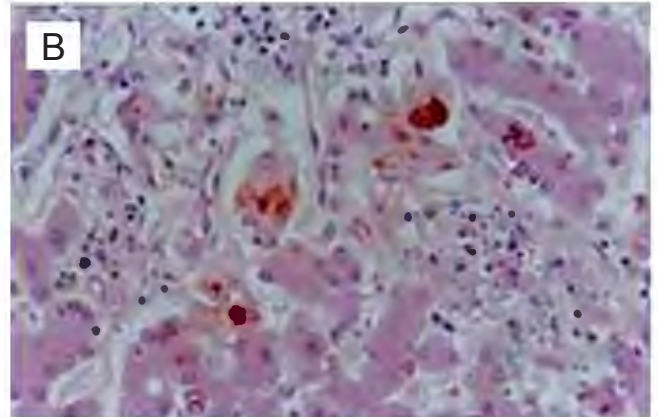
evident (**Figure 1C**), necrotic areas (**Figures 1D and 1E**) with apoptotic cells and presence of numerous *Histoplasma capsulatum* in hepatic parenchyma (**Figures 1D, 1F and 1H**).

The **Figure 2** shows hepatic microscopy of one of the five cases of abortion. In **Figure 2A** the presence of cytomegalovirus cells were observed; in the **Figure 2B** in the focal area of hepatic necrosis has the presence of intense inflammatory influx; and **Figure 2C** there are hepatocytes with intracytoplasmic and intranuclear microvacuolization.

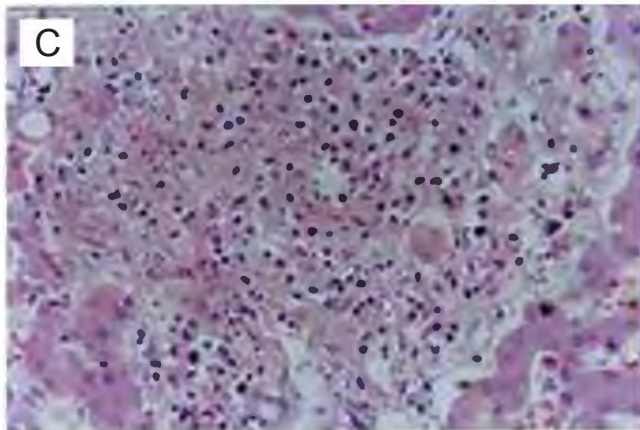
The main macroscopic changes found in the liver of autopsy from HIV positive infants in relation to color are: steatosis, areas of necrosis, cholestasis and the presence of opportunistic infections (**Graphs 1 to 5**). The **Graph 1** shows the macroscopic changes in the liver of autopsy from HIV positive children compared to staining in the 15 cases studied, revealing brownish staining in 14, wine in 3 and yellowish areas in 12 of all cases studied. The results reveal macroscopic changes in 13 cases, in at least one category, and microscopic changes consistent with steatosis in 12 of 15 cases (**Graph 2**). It was evidence the presence of cholestasis in 4 children and stillbirths in the 15 cases studied (**Graph 2**) and areas of necrosis in 7 cases (**Graph 3**). Of the five cases of abortions, two were due to the use of zidovudine by mothers. The opportunistic infections associated with HIV in pediatric autopsies most



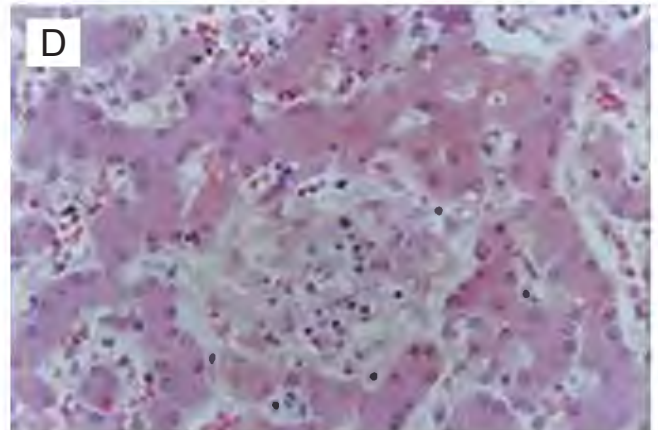
(A) (F95.147) Liver microscopy. Hepatocytes with large vacuoles deflecting the core to the periphery of the cell. Increased cell volume and with intranuclear inclusion circled with a clear halo – HE (40x).



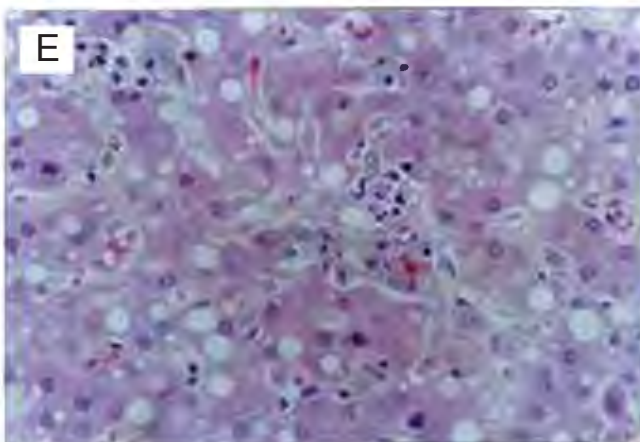
(B) (F95.147) Liver microscopy. Intracellular and intracanalicular cholestasis. Door space with discrete mononuclear influx. lobular necrosis – HE (40x).



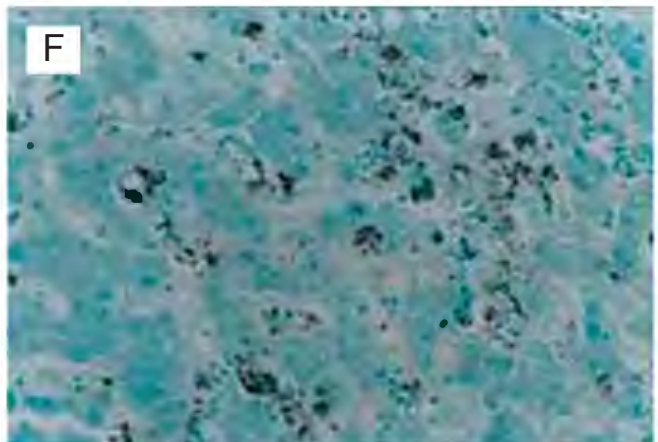
(C) (F95.147) Liver microscopy. Extensive area of periportal necrosis with numerous *histoplasma capsulatum* – HE (40x)



(D) (F95.147) Liver microscopy. Area of lobular necrosis with moderate mononuclear influx. Numerous histoplasmas – HE (40x)



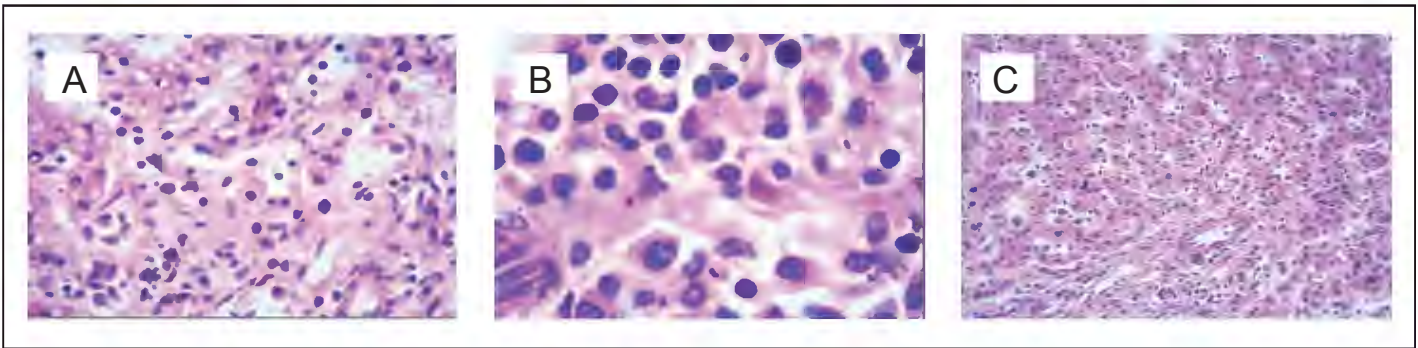
(E) (F95.147) Liver microscopy. Hepatocytes with intracytoplasmic vacuoles and intranuclear – HE (40x)



(F) (F95.147) Liver microscopy. Hepatic parenchyma showing numerous *histoplasmas capsulatum* in the cytoplasm of hepatocytes and Kupffer cells - Silver (40x)

\*Representation of 1 child of 15 cases.

**Figure 1** – Photographic documentation of hepatic microscopic alterations in child.



(A) (F96.11) Liver microscopy. Disorganization of the lobular structure. Presence of mononuclear cell influx and hepatocytes showing intracytoplasmic vacuolization with deviation from the core to the periphery of the cell. Presence of increased cell volume with basophilic nucleus and perinuclear halo (cytomegalovirus cell) (40x)

(B) (F96.11) Liver microscopy. Focal area of hepatic necrosis with presence of intense inflammatory mononuclear influx (100x)

(C) (F96.11) Liver microscopy. Hepatic parenchyma showing hepatocytes with intranuclear and intracytoplasmic microvacuolization. Door space with discrete mononuclear influx (20x)

\*Representation of 1 of 5 cases of abortion.

**Figure 2** – Photographic documentation of hepatic microscopic alterations in abortion.

frequently observed in this study correspond to cytomegalovirus infection, observed in 100% of the 15 cases analyzed, followed by histoplasmosis (13%,  $n = 2$ ) and tuberculosis (6%,  $n = 1$ ) (**Table 5 and Graph 5**).

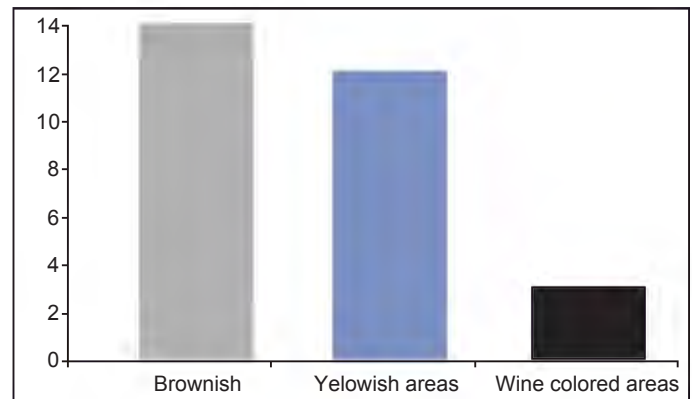
## DISCUSSION

Regarding the liver biopsy performed with the aim of clarifying the liver injury, one of the cases studied ( $n = 15$ ) showed changes consistent with hepatitis whose finding of cytomegalovirus cell enables a conclusive diagnosis of cytomegalovirus hepatitis. This paper draws attention to the usefulness of liver biopsy in clinical suspicion of opportunistic infection.

Of the 15 cases studied, only one case of HIV associated to the cytomegalovirus progressed to cirrhosis in a patient not treated with CD4 cells counts below 200 cells/uL.

There are reports in the literature in which, of the histological changes, the macrovesicular steatosis is the most common microscopic finding in the liver of HIV positive infants<sup>(2,3)</sup>. The steatosis does not seem to be related to the use of antiretroviral drugs used in the therapeutic regimen, but malnutrition and infection. The pathological changes found in the studied cases are not specifically related to HIV, but the opportunistic infections that attacked these immunocompromised patients.

The recent researches on HIV indicate the possible use of the PCR technique due to its higher sensitivity and speed in the detection of viral DNA compared to *in situ* hybridization<sup>(20)</sup>. Mainly due to its efficiency, both in the analysis of viral DNA as in the active and latent infection<sup>(19)</sup>. The detection by immunohistochemistry is jeopardized when the protein expression is low or when the protein is exported from the cell quickly. Other authors<sup>(4,11-13)</sup> highlight the importance of assessing the necropsies of abortions from HIV-positive mothers in the research related to antiretroviral



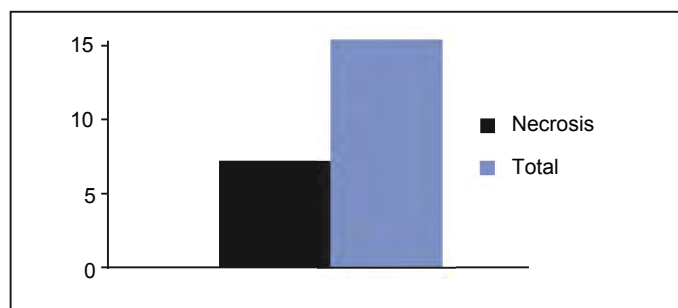
**Graph 1** – Macroscopic liver alterations of autopsy from HIV positive infants in relation to staining ( $n = 15$ ).




**Graph 2** – Macroscopic liver alterations of autopsy from HIV positive infants regarding the presence of steatosis ( $n = 15$ ).

therapy in these patients, their implications and in the analysis of factors related to vertical transmission.

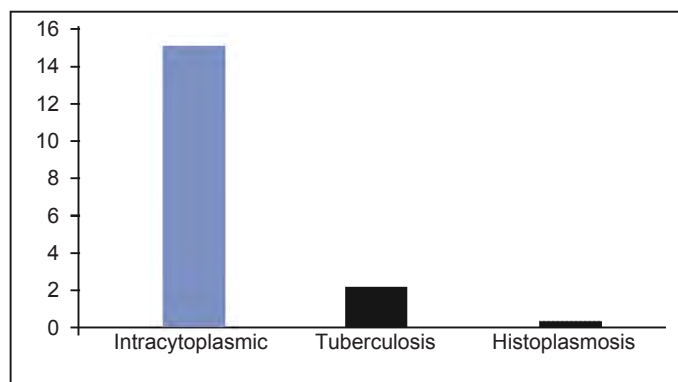
Of the five cases of abortions examined, two were from mothers treated with zidovudine. According Mofenson *et al.*<sup>(15)</sup>, the risks of



**Graph 3** – Macroscopic liver alterations of autopsy from HIV positive infants regarding the presence of necrosis (n = 15).



**Graph 4** – Macroscopic liver alterations of autopsy from HIV positive infants regarding the presence of cholestasis (n = 15).



**Graph 5** – Opportunistic infections associated with HIV in necropsies of infants (n = 15).

perinatal transmission are associated with decreased counts of T CD4<sup>+</sup> lymphocytes, of the maternal anti-HIV p24 antibodies and an increase in viral load. In one case studied, the viral load ranged from 65 thousand copies at 22 weeks of gestation with a lower number than the minimum limit (<80 copies) one month after the abortion. For the author, the occurrence of chorioamnionitis increases the risk of vertical transmission, and this change was present in one of our cases to the examination of the placenta.

Among the cases of abortions studied, two patients tested negative during prenatal care for *Toxoplasma infection goondi* (*T. goondi*).

However, in patients followed during the prenatal care that have evolved into abortion at 30 weeks of gestation, the pathological examination of the fetus and placenta revealed the presence of infection by *T. goondi*, this being responsible for the death of the fetus and the interruption of pregnancy. In another case study, although it was not a case of abortion, during the prenatal the mother also had undetectable rates for infection with *T. goondi*, however, the puerperium neonatal monitoring revealed chorioretinitis with scar in the left eye in the macular region and congenital toxoplasmosis with intracranial calcifications on computed tomography. The placental examination of this patient showed diffuse villitis with formation of giant cells suggestive of infection by *T. goondi*.

The above observations show that the routine prenatal currently used for HIV positive pregnant women may not be efficient for the detection of toxoplasmosis, which can be reactivated in these women when immunosuppressed or not. Thus, you may need to suggest a new routine prenatal in the screening of congenital infections in HIV positive pregnant women because of the serological altered results in the presence of immunosuppression.

## CONCLUSION

The hepatic alterations observed were: brownish and yellowish color, reduced consistency and increased size; the most frequent microscopic encountered was hepatic steatosis; the most prevalent opportunistic infections were cytomegalovirus, followed by histoplasmosis; the hepatic pathological changes found are not specific for HIV.

## Conflict of interests

The authors declared no conflict of interests.

## REFERENCES

1. Dufour, DR. Doenças do Fígado. In: Burtis CA, Ashwood ER, Bruns DE. Tietz: Fundamentos de Química Clínica. 6 ed. Rio de Janeiro: Guanabara Koogan. p. 691-710.
2. Albisetti M, Braegger CP, Stallmach T, Willi UV, Nadal, D. Hepatic steatosis: a frequent non-specific finding in HIV-infected children European. Eur J Pediatr. 1999;158(12):971-4.
3. Mouzaki M, Allard JP. The role of nutrients in the development, progression, and treatment of nonalcoholic fatty liverdisease. J Clin Gastroenterol. 2012;46(6):457-67.
4. Lebovics E, Thung SN, Schaffner F, Radensky PW. The liver in the acquired immunodeficiency syndrome: a clinical and histologic study. Hepatology. 1985;5(2):293-8.
5. Viriyavejakul P, Rojanasunan P, Viriyavejakul A, Punyari P, Punpoowong B, Khachansakumet V, et al. Opportunistic infections in the liver of HIV-infected patients in Thailand: a necropsy study. Southeast Asian J Trop Med Public Health. 2000;31(4):663-7.
6. Boukli N, Shetty V, Cubano L, Ricaurte M, Coelho-Dos-Reis J, Nickens Z, et al. Unique and differential protein signatures within the mononuclear cells of HIV-1 and HCV mono-infected and co-infected patients. Clin Proteomics. 2012;9(1):11.
7. Viriyavejakul P, Rojanasunan P, Viriyavejakul A, Tangwanicharoen T, Punyari P, Punpoowong B, Khachansakumet V, Wilainam P, Pongponratn E, Riganti M. Necropsy in HIV-infected patients. Southeast Asian J Trop Med Public Health. 2002 Mar;33(1):85-91.

8. Puoti M, Torti C, Ripamonti D, Castelli F, Zaltorn S, Zanini B, *et al.* Severe hepatotoxicity during combination antiretroviral treatment: incidence, liver histology, and outcome. *J Acquir Immune Defic Syndr.* 2003;32(3):259-67.
9. Viriyavejakul A, Rojanasunan P, Viriyavejakul A, Punyarit P, Punpoowong B, Khachansakumet V, *et al.* Opportunistic infections in the liver of HIV-infected patients in Thailand: a necropsy study. *Southeast Asian J Trop Med Public Health.* 2000;31(4):663-7.
10. Corcuera T, Alonso MJ, Picazo A, Gómez F, Roldán M, Abad M, *et al.* Hepatic morphological alterations induced by zidovudine (ZDV) in an experimental model. *Pathol Res Pract.* 1996;192(2):182-7.
11. Quintino MP, Simões RS, Oliveira FH, Oliveira-Filho RM, Simões MJ, Nakamura MU, *et al.* Morphological and biochemical appraisal of the liver and renal effects of indinavir on rat pregnancy. *Clin Exp Obstet Gynecol.* 2007;34(4):232-5.
12. Souza J, Storpirtis S. Atividade anti-retroviral e propriedades farmacocinéticas da associação entre lamivudina e zidovudina. *Rev Bras Ciênc Farm.* 2004;40(1):9-19.
13. Dunn D, Tess BH, Rodrigues LC, Ades AE. Mother-to-child transmission of HIV: implications of variation in maternal infectivity. *AIDS.* 1998;12(16):2211-6.
14. Tess B, Rodrigues LC, Newell ML, Dunn DT, Lago TD. Breastfeeding genetic, obstetric and other risk factors associated with mother-to-child transmission of HIV-1 in Sao Paulo State, Brazil. *Sao Paulo Collaborative Study for Vertical Transmission of HIV-1.* *AIDS.* 1998;12(5):513-20.
15. Mofenson LM, Lambert JS, Stiehler ER, Bethel J, Meyer WA 3rd, Whitehouse J, *et al.* Risk factors for perinatal transmissions of human immunodeficiency virus type 1 in women treated with zidovudine. *Pediatric AIDS Clinical Trials Group Study 185 Team.* *N Eng J Med.* 1999;341(6):385-93.
16. Cavarelli M, Scarlatti G. HIV-1 co-receptor usage: influence on mother-to-child transmission and pediatric infection. *J Transl Med.* 2011;9(Suppl 1):S10.
17. Betancourt TS, Abrams EJ, McBain R, Fawzi MC. Family-centred approaches to the prevention of mother to child transmission of HIV. *J Int AIDS Soc.* 2010;13(Suppl 2):S2.
18. Nakajima N, Ionescu P, Sato Y, Hashimoto M, Kuroita T, Takahashi H, *et al.* In situ hybridization AT-tailing with catalyzed signal amplification for sensitive and specific in situ detection of human immunodeficiency virus-1 mRNA in formalin-fixed and paraffin-embedded tissues. *Am J Pathol.* 2003;162(2):381-9.
19. Puoti M, Torti C, Ripamonti D, Castelli F, Zaltorn S, Zanini B, *et al.* severe hepatotoxicity during combination antiretroviral treatment: incidence, liver histology, and outcome. *J Acquir Immune Deficienci Syndr.* 2003;32(3):259-67.
20. Adih W, Selik RM, Hu X. Trends in diseases reported on US death certificates that mentioned HIV infection, 1996–2006. *J Int Assoc Physicians AIDS Care (Chic).* 2011;10(1):5-11.
21. Centers for Disease Control and Prevention. 1994 Revised classification system for human immunodeficiency virus infection in children less than 13 years of age. Official authorized addenda: human immunodeficiency virus infection codes and official guidelines for coding and reporting ICD-9-CM. *Morbidity and Mortality Weekly Report.* 1994;43(RR-12):1-28.
22. Nuovo GJ, Margiotta M, MacConnell P, Becker J. Rapid in situ detection of PCR-amplified HIV-1 DNA. *Diagn Mol Pathol.* 1992;1(2):98-102.
23. Centers for Disease Control. Revision of the CDC surveillance: case definition for acquired immunodeficiency syndrome. *Morbidity and Mortality Weekly Report.* 1987;36(Suppl):1-15.

**Address to correspondence:**

**LUCIENE DE CARVALHO CARDOSO WEIDE**  
 Hospital Universitário Antônio Pedro (HUAP), 4º andar  
 Departamento de Patologia  
 Rua Marquês do Paraná, 303 – Centro  
 Niterói (RJ), Brasil  
 CEP: 24033-900  
 Tel: +55 (21) 2629-9111  
 E-mail: lucienecardoso@gmail.com

Received on: 03.22.2013  
 Approved on: 11.29.2013